



CASE REPORT:

Reshaping Smiles:

A Successful Clinical Case with Botulinum Toxin for Gummy Smile Reduction

Remodelación de sonrisas:

un caso clínico de éxito con toxina botulínica para la reducción de la sonrisa gingival

Alessandra Kuhn Dall'Magro DDS, PhD, MSc¹ <https://orcid.org/0000-0001-7148-5111>

Felipe Gomes Dallepiane DDS, MSc student² <https://orcid.org/0000-0001-9677-9984>

Júlia Calliari Martin DDS³ <https://orcid.org/0000-0002-3229-1899>

Priscila Nicolini³ <https://orcid.org/0000-0001-8269-0268>

Paulo Ricardo Marques Stefanello DDS³ <https://orcid.org/0000-0003-2714-3290>

Marciele Cristiane Spanenberg Führ DDS³ <https://orcid.org/0000-0002-3054-0775>

Micheline Sandini Trentin DDS, PhD, MSc³ <https://orcid.org/0000-0001-5040-3578>

Eduardo Dall'Magro DDS, PhD, MSc¹ <https://orcid.org/0000-0001-6138-1570>

João Paulo De Carli DDS, PhD, MSc³ <https://orcid.org/0000-0002-4705-6226>

1. Clinic, FacialMed Centter, Passo Fundo, Brazil.

2. Department of Dentistry, Faculty of Dentistry, Federal University of Santa Catarina, Florianópolis, Brazil.

3. Department of Dentistry, Faculty of Dentistry, University of Passo Fundo, Passo Fundo, Brazil.

Correspondence to: Felipe Gomes Dallepiane - dallepianefe@gmail.com

Received: 2-II-2024

Accepted: 14-III-2024

ABSTRACT: The use of botulinum toxin (BTX) represents an effective and safe approach in treating the gummy smile, reducing excessive gum exposure during smiling. This minimally invasive procedure can yield remarkable aesthetic results and contribute to an increase in the patient's self-confidence. The aim of this study is to report a clinical case of a female patient undergoing treatment to correct a gummy smile. The case study involves a 21-year-old patient with excessive gum exposure (5mm when smiling) who sought dental treatment. The origin of her gummy smile was mixed, and the treatment involved the application of 6 units of BTX type A at three specific points on the face. No complications were observed during the three-month follow-up period. Based on the case report, it can be concluded that BTX application for gummy smile treatment proved to be effective, safe, and comfortable in terms of recovery. The BTX approach to correcting a gummy smile is considered safe and entails straightforward recovery, producing satisfactory results that contribute to the improvement of aesthetics and the patient's well-being.



KEYWORDS: Gummy smile; Botulinum toxin; Orofacial harmonization.

RESUMEN: El uso de toxina botulínica (BTX) representa un enfoque eficaz y seguro para el tratamiento de las sonrisas gingivales, reduciendo la exposición excesiva de las encías durante la sonrisa. Este procedimiento mínimamente invasivo puede producir resultados estéticos notables y contribuir a aumentar la confianza del paciente en sí mismo. El objetivo de este estudio es presentar el caso clínico de una paciente que se sometió a un tratamiento para corregir una sonrisa gingival. Se trata de una paciente de 21 años con una exposición gingival excesiva (5mm al sonreír) que solicitó tratamiento odontológico. El origen de su sonrisa gingival era mixto y el tratamiento consistió en la aplicación de 6 unidades de BTX tipo A en tres puntos concretos de la cara. No se observaron complicaciones durante los tres meses de seguimiento. Basándonos en el informe del caso, se puede concluir que la aplicación de BTX para el tratamiento de la sonrisa gingival demostró ser eficaz, segura y cómoda en términos de recuperación. El enfoque de BTX para la corrección de la sonrisa gingival se considera seguro y de fácil recuperación, y produce resultados satisfactorios que contribuyen a mejorar la estética y el bienestar del paciente.

PALABRAS CLAVE: Sonrisa gingival; Toxina botulínica; Armonización orofacial.

INTRODUCTION

An esthetic smile is characterized by providing facial esthetic correlation, lip dynamics, and harmonizing the red and white aesthetics of the oral cavity (1). On the other hand, a gummy smile is defined as a non-pathological esthetic condition that results in disharmony, where an excessive amount of gum tissue is visible when smiling (2). The etiology of a gummy smile involves factors such as abnormal tooth eruption, lip hyperactivity, excessive vertical maxillary growth, tooth extrusion, overbite, as well as a short and prominent upper lip (3).

There are different treatments for a gummy smile, which are defined based on the etiology of the problem in various clinical cases (4). These treatments may include periodontal surgeries (5), laser surgeries (6), the application of botulinum toxin

(BTX) (7), orthodontics (8), orthognathic surgeries (9), lip repositioning (10), polyester threads (11), or even a combination of the treatments mentioned above.

After proper clinical diagnosis and establishing the etiology, treatment with BTX can be a therapeutic alternative when a gummy smile is caused by labial hypercontraction, as suggested in cases of muscular hyperfunction. BTX treatment is considered an effective alternative for reducing a gummy smile due to the ease and safety of the applications (12). The advantages of this treatment include ease and safety during application, the use of a reduced amount of the product, rapid action, low risk, and a reversible effect, which is not the case with invasive surgical treatments (13).

In light of the foregoing, the aim of this study is to report a clinical case describing the

use of BTX in cases of gummy smile associated with muscular hyperfunction, as well as to present the results obtained.

CASE REPORT

Following the patient's signature on an Informed Consent Form (ICF), this case was submitted and approved by the Research Ethics Committee of UPF (CEP/UPF) (Opinion number 5.785.215).

A 21-year-old female patient, of fair complexion, sought dental care for the evaluation and possible treatment of a gummy smile. She had aesthetic concerns regarding gum exposure when smiling and wished to improve this aspect.

During the anamnesis, the patient reported not having any drug allergies or significant health problems. She had previously undergone local anesthesia without any complications (ASA Classification I).

In the same session, photographs were taken, and facial analysis was conducted (Figure 1). The patient exhibited a facial pattern type I, with no apparent scars on the facial region and a Fitzpatrick skin phototype type II. Facial proportions were measured, with the upper third measuring 6.5cm, the middle third 6.5cm, and the lower third 7cm.

The gummy smile was determined to be mixed, and three points for the application of BTX Type A (Botox-Allergan Aesthetics Brazil-Guarulhos, SP) were established (Figure 2).

After proper dilution of the product, 2 IU of toxin were injected at each point, with half a needle introduced and applied slowly, totaling 6 IU. During the first session, complete resolution of the patient's gummy smile was observed, with the dose used and treatment being effective immediately.

With this in mind, a post-operative follow-up of 90 days was proposed to assess the effectiveness and stability of the therapeutic effects achieved. Figure 3 shows the appearance of the smile 30 days after the first session, with noticeable positive results and no evident changes. Figure 4 shows the clinical appearance after 60 days, still without significant alterations.

Figure 5 shows the clinical appearance of the smile 90 days after the first session, with no significant changes observed in the measurements. Therefore, the results obtained in the first session remained stable.

It should be noted that the patient had a 5 mm gummy smile initially, and in 90 days, there was no return to gingival exposure at those levels or clinically visible alterations.

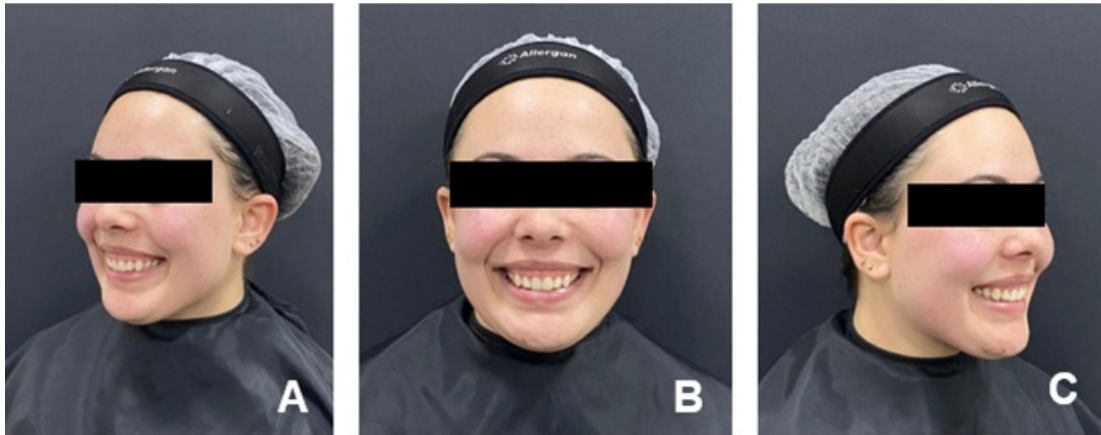

Figure 1. Initial clinical appearance of the smile during the anamnesis A. Left profile B. Frontal C. Right profile.

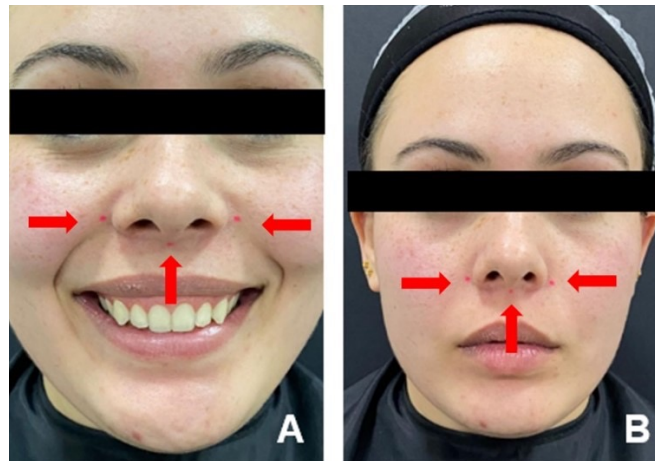

Figure 2. Three injection points for the toxin (red spheres): central region, at the point of greatest contraction of the nasolabial sulcus, and two other points lateral to the wing of the nose.

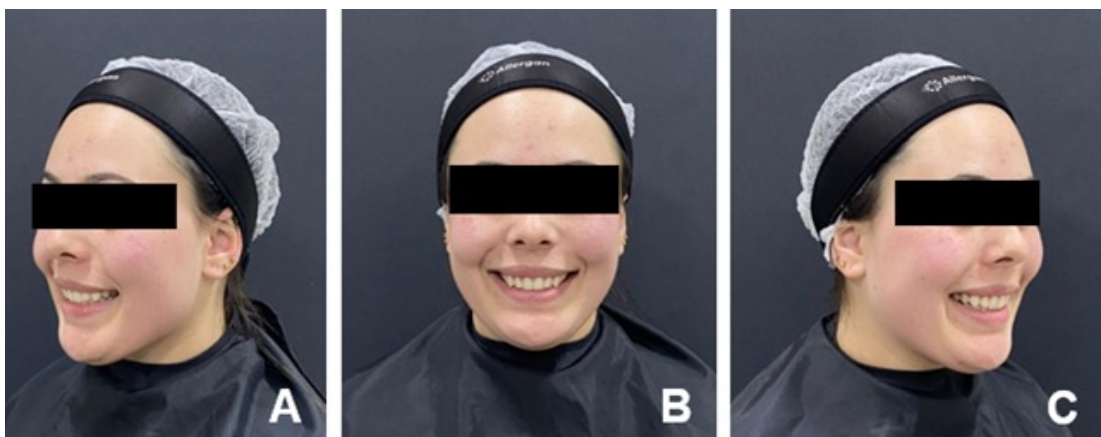

Figure 3. Clinical appearance of the smile 30 days after the procedure: A. Left profile; B. Frontal; C. Right profile.

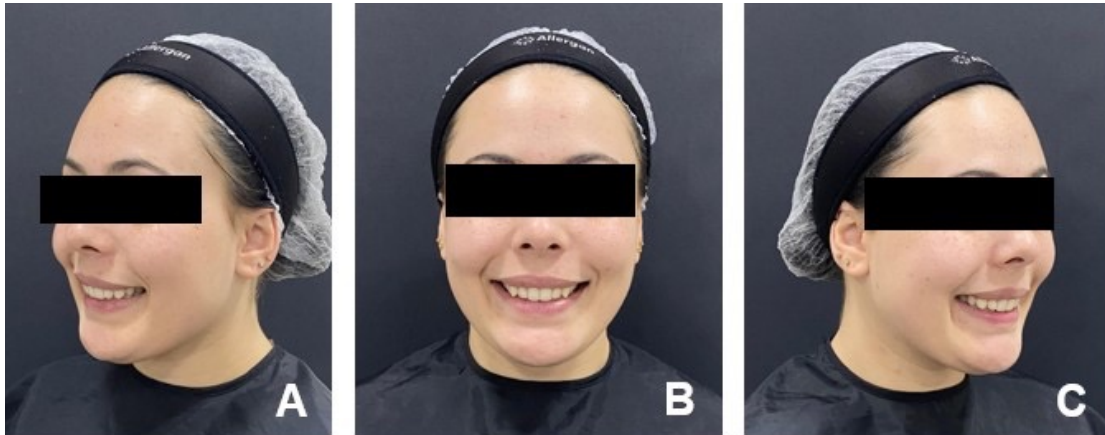


Figure 4. Clinical appearance of the smile 60 days after the procedure: A. Left profile; B. Frontal; C. Right profile.

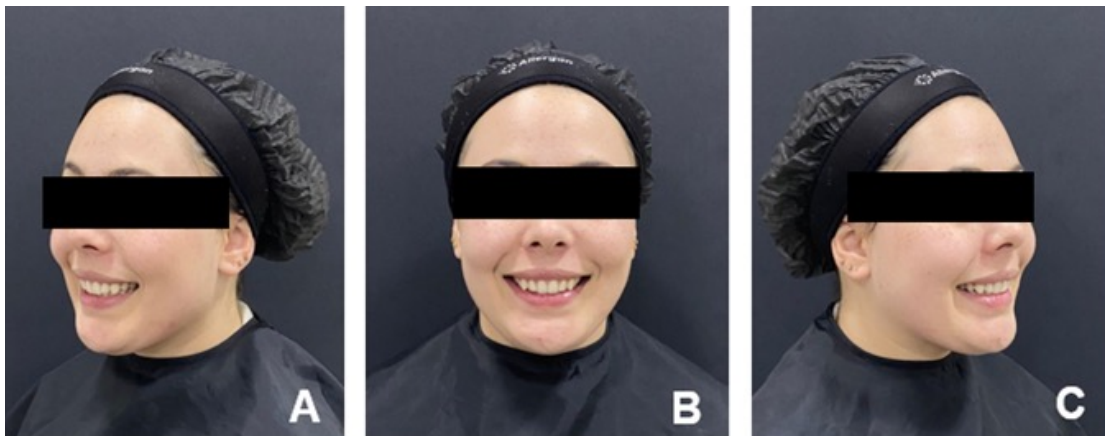

Figure 5. Clinical appearance of the smile 90 days after the procedure: A. Left profile; B. Frontal view; C. Right profile.

DISCUSSION

The excessive exposure of gingival tissue when smiling is a common concern among dental patients and is often seen as an aesthetic issue (14). The patient in this case had an initial gingival exposure of 5mm, with the etiological factor diagnosed clinically, attributed to the hyperfunction of the upper lip.

BTX has been widely used in the control and treatment of muscle hyperfunction, not only in the aesthetic field but also in cases of temporoman-

dibular disorders (15). Application points lateral to the nasal wing can be used in the conventional technique for treating anterior gummy smile. In cases of posterior gummy smile, the product should be applied at the point of greatest contraction of the nasolabial sulcus during smiling and 2cm laterally to the first point. In cases of mixed gummy smile, application should be performed at all points (13).

The use of BTX following the Yonsei point technique involves three muscles: the levator labii superioris and ala of the nose, the levator labii

superioris, and the zygomatic minor. This technique represents a safe and effective point for the application of BTX type A, with no complications observed (16). The patient in this case had a mixed gummy smile, with extensive gum exposure when smiling, greater than 3mm. Therefore, the proposed treatment was to perform BTX type A injections at three points: two lateral to the nose wing and one midpoint in the nasolabial sulcus.

Razmaite and Trakiniene (2021) reviewed the main points of BTX application in the treatment of gummy smiles, highlighting these points as they pass through the major target muscles of the techniques described in the literature: the levator labii superioris, the levator labii superioris and ala of the nose, and the zygomatic minor (17). Similarly to what was done in this study, Mazzuco and Hexsel (2010) also recommend the application of BTX at a central point in the nasolabial sulcus in cases of posterior or mixed gummy smiles (13).

The average units for bilateral application to the nose wings range from 4 to 6 IU, with the severity of the gummy smile being the main factor in determining the required quantity for treatment, and in extreme cases justifying a slight increase in dosage (14). In the case discussed in this study, an average of 2 IU of BTX type A was used at each of the three points, totaling 6 IU required to resolve the case.

The patient in the described case remained under postoperative follow-up, with visible stability of the results up to 90 days after the procedure. The reversibility of this technique remains a disadvantage, with a duration of 4 to 6 months being the observed average for the effects of type A BTX treatments. The stability of BTX results in cases of gummy smile is up to 8 weeks, with no complete return to initial measurements within 12 weeks (18), which aligns with the results observed in the clinical case presented in this study (90 days).

It is of utmost importance to emphasize that the treatment in question has temporary results, and the final outcome achieved may vary from patient to patient. However, its safety, reversibility, and the fact that it is a less invasive procedure are still the main advantages of this technique. Therefore, it is suggested that further clinical studies with longer follow-up periods be conducted to progressively gain a better understanding of the long-term effects of BTX application in the treatment of gummy smile.

CONCLUSION

In light of the case presented, it can be concluded that the application of BTX in the treatment of gummy smile is a safe and easily executable technique for the patient. The obtained results were satisfactory both from a professional perspective and from the patient's personal perspective, restoring aesthetics and well-being.

RIGHT TO PRIVACY AND INFORMED CONSENT

The authors have obtained the written informed consent of the patients or subjects mentioned in the article. The corresponding author is in possession of this document.

CONFLICT OF INTEREST

The authors have no conflicts of interest to declare.

PROTECTION OF HUMAN AND ANIMAL SUBJECTS

The authors declare that the procedures followed were in accordance with the regulations of the relevant clinical research ethics committee and with those of the Code of Ethics of the World Medical Association (Declaration of Helsinki).

CONFIDENTIALITY OF DATA

The authors declare that they have followed their work center protocols on access to patient data and for its publication.

AUTHOR CONTRIBUTION STATEMENT

Conceptualization and design: A.K.D., F.G.D., and J.C.M.

Literature review: A.K.D., and J.C.M.

Methodology and Validation: P.N., and F.G.D.

Formal analysis: A.K.D., and J.P.D.C.

Investigation and data collection: A.K.D., P.R.M.S., and M.C.S.F.

Resources: A.K.D.

Data analysis and interpretation: P.N., P.R.M.S., and M.C.S.F.

Writing-original draft preparation: M.S.T., and J.P.D.C.

Writing-review & editing: F.G.D.

Supervision: M.S.T., E.D., and J.P.D.C.

Project administration: A.K.D., M.S.T., E.D., and J.P.D.C.

Funding acquisition: A.K.D.

REFERENCES

1. Sabbah A. Smile Analysis: Diagnosis and Treatment Planning. *Dent Clin North Am.* 2022; 66 (3): 307-341.
2. Mercado-García J., Rosso P., Gonzalvez-García M., Colina J., Fernández JM. Gummy smile: Mercado-Rosso classification system and dynamic restructuring with hyaluronic acid. *Aesthetic Plast Surg.* 2021; 45: 1-12.
3. Pavone A.F., Ghassemian M., Verardi S. Gummy smile and short Tooth Syndrome- Part 1: Etiopathogenesis, classifications, and diagnostic guidelines. *Compend Contin Educ Dent* 2016; 37 (2): 102-7.
4. Abdullah W.A., Khalil H.S., Alhindi M.M., Marzook H. Modifying gummy smile: a minimally invasive approach. *J Contemp Dent Pract* 2014; 15 (6): 821-826.
5. Ribeiro F.V., Hirata D.Y., Reis A.F., Santos V.R., Miranda T.S., Faveri M., Duarte P. M. Open- flap versus flapless esthetic crown lengthening: 12- month clinical outcomes of a randomized controlled clinical trial. *J Periodontol*, 2014; 85 (4): 536-44.
6. Mossaad A.M., Abdelrahman M.A., Kotb A.M., Alolayan A.B., Elsayed S.A.H. Gummy smile management using diode laser gingivectomy versus botulinum toxin injection- A prospective study. *Ann. Maxillofac. Surg* 2021; 11 (1): 70.
7. Rojo-Sanchis C., Montiel-Company J.M., Tarazona-Álvarez B., Haas-Junior O.L., Peiró-Guijarro M. A., Paredes-Gallardo V., Guijarro-Martínez R. Non-Surgical Management of the Gingival Smile with Botulinum Toxin A-A Systematic Review and Meta-Analysis. *J Clin Med* 2023; 12 (4): 1433.
8. Parayaruthottam P., Antony V. Midline mini-implant-assisted true intrusion of maxillary anterior teeth for improved smile esthetics in gummy smile. *Contemp Clin Dent* 2021; 12 (3): 332.
9. Rizzi R.I., Portes M.I.P., Ertty E., Meloti F., An T.L., De Almeida C.M. Aesthetic perception of smile in long face pattern patients who underwent maxillary impaction with miniplates or orthognathic surgery. *J Stomatol Oral Maxillofac. Surg* 2022; 123 (5): 498-504.
10. Haddadi P., Zare H., Azadikhah A. Lip repositioning, a solution for gummy smile. *Front Dent* 2021; 18.

11. Horn R.O., Joly J.C. Treatment of Gummy Smile Combining Crown Lengthening, Lip Repositioning and The Use of Polyester Threads. *Clin Adv Periodontics* 2022; 13 (1): 42-45.
12. Zengiski A.C.S., Basso I.B., Cavalcante-Leão B.L., Stechman-Neto J., Santos R.S., Guariza-Filho O., Zeigelboim B.S., Taveira K.V.M., de Araujo C.M. Effect and longevity of botulinum toxin in the treatment of gummy smile: a meta-analysis and meta-regression. *Clin Oral Investig* 2022; 26: 109-117.
13. Mazzuco R., Hexsel D. Gummy smile and botulinum toxin: A new approach based on the gingival exposure area. *J Am Acad Dermatol* 2010; 63 (6): 1042-51.
14. Dym H., Pierre R. Diagnosis and Treatment Approaches to a "Gummy Smile". *Dent Clin North Am* 2020; 64 (2): 341-49.
15. Kuhn-Dall'magro A., Calza S.C., Lauxen J., Santos R., Valcanaia T.D.C., Dall'magro E. Tratamento do sorriso gengival com toxina botulínica tipo A: relato de caso. *RFO UPF* 2015; 20 (1): 81-87.
16. Duruel O., Ataman-Duruel E.T., Berker E., Tözüm T.F. Treatment of Various Types of Gummy Smile With Botulinum Toxin-A. *J. Craniofac. Surg* 2019; 30 (3): 876-78.
17. Razmaite A., Trakiniene G. The effect of botox for the correction of the gummy smile: A systematic review. *Stomatologija* 2021; 23 (3): 63-8.
18. Chagas T.F., Almeida N.V., Lisboa C.O., Ferreira D.M.T.P., Mattos C.T., Mucha J.M. Duration of effectiveness of Botulinum toxin type A in excessive gingival display: a systematic review and meta-analysis. *Braz Oral Res* 2018; 32 (30): 1-11.