

## Difficulties in the identification of corpses and skeletal remains by Forensic Odontology in Costa Rica: Analysis of 165 autopsies

José Manuel Fernández Chaves<sup>1</sup>

1. Espec. Odontología Forense. Patología y Cirugía Oral. M.Sc. Administración de Servicios de Salud Sostenible. Profesor Facultad de Odontología Universidad de Costa Rica. Unidad de Odontología Forense, Departamento de Medicina Legal, Organismo de Investigación Judicial. Heredia, Costa Rica. ORCID ID: <https://orcid.org/0000-0001-6478-5407>



Corresponding author: Dr. M.Sc. José Manuel Fernández Chaves ---jfernandezch@Poder-judicial.co.cr

Recibido: 07-07-2022

Aceptado: 24-08-2022

### Abstract

**Introduction:** In Costa Rica the elaboration of dental records or clinical files is not performed routinely in all patients as it is required by law in many countries. The completion of the dental record is only regulated by the Code of Ethics of the Colegio de Cirujanos Dentistas de Costa Rica (Board of Dental Surgeons of Costa Rica), which means that failure to do so is considered an ethical-disciplinary offense with few consequences for the professional; however, it has serious consequences in the efforts to identify a person. This study aims to describe the impact of the absence or poor quality of antemortem data in identification cases performed by the Forensic Odontology Unit of the Department of Legal Medicine over a period of almost eight years (2015-2022). **Materials and Methods:** A detailed review was performed in the database of the Forensic Medicine System (SIMEL) of the Legal Medicine Department of the Judicial Investigation Organism of the totality of interconsultation requests of the Forensic Pathology Section from January 2015 to August 2022. The information collected was tabulated in Excel and included both the results of the expert analysis and the characteristics of the available antemortem information. **Results:** The analysis of the data made it possible to determine that in a period of almost 8 years 165 assessments were carried out for identification purposes, of which 51 individuals were identified, 9 cases presented insufficient information and 105 had no dental files. **Conclusions:** A complete dental record is indispensable for a positive identification; an incomplete or non-existent record nullifies the possibility of identifying a human being.

### Key words

*Clinical file, dental record, dentistry, antemortem, identification*

*Source: MeSH (Medical Subject Headings)*

## Introduction

The identification of corpses and skeletal remains is one of the best-known areas of forensic dentistry, whether in mass disasters (1)(2) or in any other event where dental structures are useful as a means of identification because they withstand high temperatures and severe environmental conditions (3)(4).

The identification process by Forensic Odontology is based on the comparison of antemortem information (dental records) and postmortem information collected to make a comparison (5)(6) that allows a reliable identification (7).

One of the vital factors to identify a person is to have adequate antemortem dental information, the dental symbology should be understandable and universal (8), that is to say that any dental professional should read a file and interpret it easily, unfortunately in Costa Rica previous studies have determined that 53.3% of the physical files and 33.3% of the digital systems had incomplete clinical examination (8)(9).

A detailed record should include, in addition to the usual annotations of treatments performed, all the information that corresponds to the current technological development such as radiological images in 2D, 3D (10-13) and three-dimensional scans that are replacing conventional dental impressions and models in plaster, as well as extraoral and intraoral photographs since they are all useful in identification (14)(15).

## Materials and Methods

Using the Forensic Medicine System (SIMEL), a detailed review of each of the requests made by the Forensic Pathology Section was carried out and only those related to identification of corpses or skeletal remains were considered. The period analyzed covered from January 2015, when the Forensic Odontology Unit of the Forensic Medicine Department was created, until August 2022.

An Excel table was designed where 165 cases were included and were divided into: no antemortem information, inconsistent information (those that had no clear or insufficient information to make a positive identification) and finally those that were positively identified.

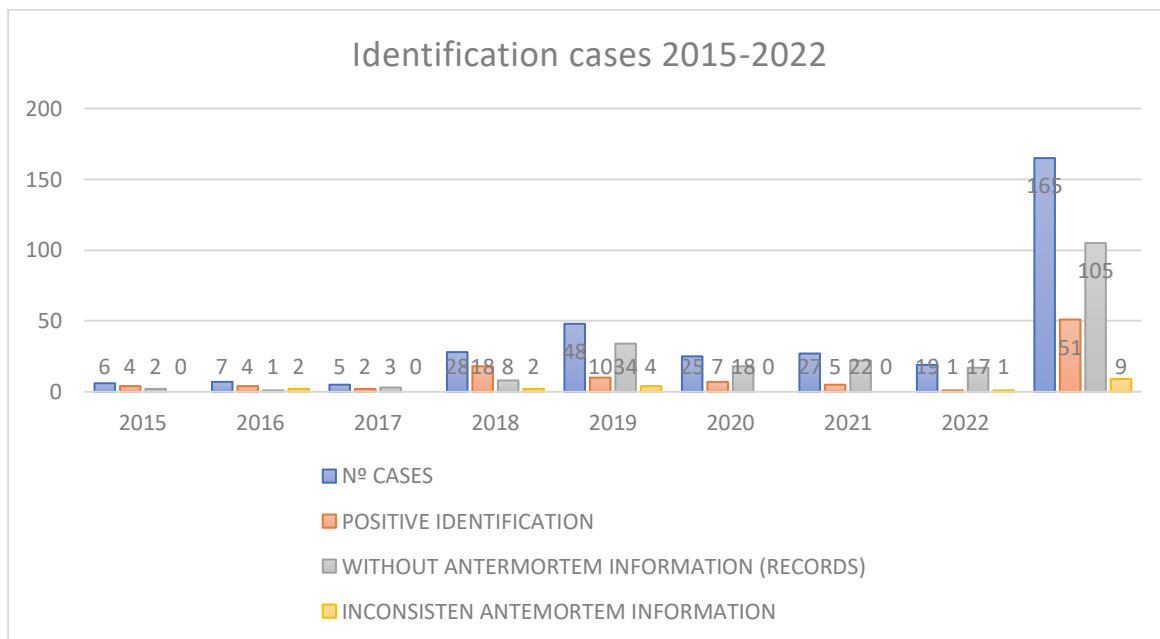
## Results

According to the information analyzed, 165 consultation requests were made for human identification by forensic odontology, of which 105 (63.65%) had no antemortem dental records, 9 cases (5.45%) had inconsistent information and finally 51 cases (30.90%) were positively identified, as shown in table 1 and figure 1.

**Table 1.** Cases of identification of persons analyzed by the Forensic Odontology Unit of the Department of Forensic Medicine from 2015-2022.

Identification cases 2015-2022				
YEAR	Nº CASES	POSITIVE IDENTIFICATION	WITHOUT ANTERMORTEM INFORMATION (RECORDS)	INCONSISTEN ANTERMORTEM INFORMATION
2015	6	4	2	0
2016	7	4	1	2
2017	5	2	3	0
2018	28	18	8	2
2019	48	10	34	4
2020	25	7	18	0
2021	27	5	22	0
2022	19	1	17	1
	165	51	105	9

Figure 1 shows how there is a significant increase in cases (1:8) of identification when comparing the years 2015 to 2017 with the years 2019-2022, especially 2019 with 48 cases representing almost 30% of the total sample of 8 years, and a ratio of 8 times more cases when comparing 2019 with 2015.



**Figure 1.** Distribution by year cases of identification of corpses and skeletal remains.

## Discussion

The data allow us to conclude that there is an increase in the number of people to be identified as of the year 2018, most of these are related to cases of delinquency and organized crime, a situation that does not escape the reality of many other countries. (16)(17)

In relation to the result of the identifications it is indisputable that the absence of antemortem information or poor quality makes it impossible to perform an identification by dental methods since almost two thirds of the cases (63.65%) do not have clinical records, without underestimating the records that are deficient (5.45%), these findings are compatible with those found in research conducted in Costa Rica with respect to the realization of dental clinical records and the low level of importance given to them by dental professionals as a method of identification. (8)(9)

## Conclusions

Identification by forensic odontology is one of the internationally recognized methods, and it is characterized because it is fast and economical when compared with DNA analysis; however, it is useless if there is no antemortem information on the person to be identified.

In this study it is evident that the absence of dental records makes it impossible to identify a person quickly, which not only has a high cost at the national level due to the techniques involved in DNA testing, but also has a very high human cost.

The waiting time for families to find out whether it is one of their family members has a great emotional impact that could be avoided if dental professionals would take a few minutes to fulfill their duty of making a file.

The need for legislation that makes the creation and preservation of dental records mandatory for identification purposes is necessary in Costa Rica.

## Competing interests

The author(s) declared no potential conflicts of interest with respect to the research and/or publication.

## References

1. Kolude B, Adeyemi B, Taiwo J, ... OS-A of I, 2010 undefined. The role of forensic dentist following mass disaster. *Ann Ibadan Postgrad Med* [Internet]. 2010 Dec [cited 2022 Sep 7];8(2):111–7. Available from: <https://www.ajol.info/index.php/aipm/article/view/71826>
2. Valenzuela A, ... SM-DLH-I journal of, 2000 undefined. The application of dental methods of identification to human burn victims in a mass disaster. Springer [Internet]. 2000 [cited 2022 Sep 7];113(4):236–9. Available from: <https://link.springer.com/article/10.1007/s004149900099>
3. R George WTAYPD. The effects of temperature on extracted teeth of different age groups: A pilot study. *J Forensic Dent Sci*. 2017;9:165.
4. K Rötzscher CGSB. The effects of high temperatures on human teeth and dentures. *Int Poster J Dent Oral Med*. 2004;6:1–4.
5. Sweet D. Forensic dental identification. [cited 2021 Mar 4]; Available from: [www.forensidentistryonline.org/Forensic\\_pages\\_1/ident\\_guidelines.htm](http://www.forensidentistryonline.org/Forensic_pages_1/ident_guidelines.htm).
6. Dvi I, Committee S, Guidelines QM. Interpol Standing Committee on Disaster Victim Identification. :1–15.
7. Fonseca GM, Cantín M, Lucena J, Asociado P. *Odontología Forense II: La Identificación Inequívoca*. Int. J. Odontostomat. 2013.
8. Hernández Carazo D, Solano Romero K, Torres Guevara E, Trejos Cisneros JJ, Fernández Chaves JM. Determinación de la simbología más utilizada en expedientes odontológicos en Costa Rica en el año 2019 con fines de identificación de seres humanos. *Med leg Costa Rica*. 2020;37(1):179–91.
9. Fernández Chaves JM. Utilidad de expedientes odontológicos disponibles en Costa Rica en el año 2018 para la identificación de víctimas de desastres según el protocolo de INTERPOL. *Rev Med Leg Costa Rica* [Internet]. 2019 Mar [cited 2021 Mar 11];36(1):32–42. Available from: <https://www.scielo.sa.cr/pdf/mlcr/v36n1/2215-5287-mlcr-36-01-32.pdf>
10. Du Chesne A, Benthaus S, Teige K, Brinkmann B. Post-mortem orthopantomography - An aid in screening for identification purposes. *Int J Legal Med*. 2000;113(2):63–9.
11. Evans S, Jones C, Plassmann P. 3D imaging in forensic odontology. *J Vis Commun Med* [Internet]. 2010 Jun 16;33(2):63–8. Available from: <http://search.ebscohost.com/login.aspx?direct=true&db=mnh&AN=20557154&lang=es&site=eds-live>
12. Oktay AB. Human identification with dental panoramic radiographic images. In: *IET Biometrics. Institution of Engineering and Technology*; 2018. p. 349–55.
13. Zhou J, Abdel-Mottaleb M. A content-based system for human identification based on bitewing dental X-ray images. *Pattern Recognit*. 2005 Nov;38(11):2132–42.
14. Mou Q nan, Ji L ling, Liu Y, Zhou P rong, Han M qi, Zhao J min, et al. Three-dimensional superimposition of digital models for individual identification. *Forensic Sci Int* [Internet]. 2021;318:110597. Available from: <https://doi.org/10.1016/j.forsciint.2020.110597>
15. K S. Progress in digital dentistry: The practical use of intraoral scanners. *Dent Mater J* [Internet]. 2020 [cited 2021 Sep 5];39(1):52–6. Available from: <https://pubmed.ncbi.nlm.nih.gov/31723066/>
16. Carolina Robledo Silvestre, May-ek Querales-Mendoza. Presentación del dossier. *Desaparición de personas en el mundo globalizado: desafíos desde América Latina. Íconos-Revista Ciencias Soc No 67*. 2020;24(67):7–15.

17. Argüello Cabrera L, Argüello Cabrera L. Homicidios, cotidianidad y la ‘Guerra contra el Narcotráfico’. Atoyac de Álvarez, Guerrero (2007-2014). Iztapalapa Rev ciencias Soc y humanidades [Internet]. 2019 Jul 1 [cited 2022 Sep 9];40(87):175–203. Available from: [http://www.scielo.org.mx/scielo.php?script=sci\\_arttext&pid=S2007-91762019000200175&lng=es&nrm=iso&tlng=es](http://www.scielo.org.mx/scielo.php?script=sci_arttext&pid=S2007-91762019000200175&lng=es&nrm=iso&tlng=es)



Attribution (BY-NC) - (BY) You must give appropriate credit, provide a link to the license, and indicate if changes were made. You may do so in any reasonable manner, but not in any way that suggest the licensor endorses you or your use. (NC) You may not use the material for commercial purposes.